

Contrails

FOREWORD

The investigations described in this report were carried out during the period from May 1, 1962 to February 25, 1963. The research was conducted under Contract No. AF 33 (657)-9021, Project No. 6302, "Toxic Hazards of Propellants and Materials," and Task No. 630202, "Pharmacology-Biochemistry," for the Toxic Hazards Branch, Physiology Division, Biomedical Laboratory, Wright-Patterson Air Force Base, Ohio. The project was carried out by José M.R. Delgado, M.D., Sc. D., Associate Professor of Physiology, Yale University School of Medicine. The Contract Monitor was Dr. Kenneth C. Back. Some of the surgical and electronic equipment was furnished by research funds from the Yale University School of Medicine, Office of Naval Research, and the United States Public Health Service. The decaborane was supplied by the 6570th Aerospace Medical Research Laboratories, Aerospace Medical Division, Wright-Patterson Air Force Base, Ohio.

The animal experimentation reported herein was conducted according to the "Principles of Laboratory Animal Care," established by the National Society for Medical Research.


Contrails

ABSTRACT

The effects of intraperitoneal injection of decaborane have been investigated in monkeys with electrodes permanently implanted in the brain. One single injection of 5 mg/kg produced a marked behavioral depression, with only moderate electroencephalographic modifications, followed by death in 18 hours. Four daily doses of 3 mg/kg produced depression, somnolence, twitching in both arms, accompanied by bursts of high-voltage activity, localized in the internal capsule. Death occurred 3 days later. Daily doses of 1 mg/kg up to a total of 14 mg/kg produced depression, muscular twitching, anorexia, and a typical electroencephalographic pattern, but the animals recovered completely. Depression may be related to reticular system involvement. Motor symptomatology could depend on disturbances of heavily myelinated motor axons which may have a special affinity for the liposoluble decaborane. Hypothalamic involvement was questionable, but neighboring structures, especially the internal capsule showed electrical disturbances.

PUBLICATION REVIEW

This technical documentary report has been reviewed and is approved.



JOS. M. QUASHNOCK
Colonel, USAF, MC
Chief, Biomedical Laboratory

INTRODUCTION

The use of decaborane as high-energy fuel and propellant represents a definite risk for the personnel involved in its production and handling because of the high toxicity of the product. Several cases of intoxication have already occurred (ref. 3 and 5), and as decaboranes are very promising as a source of energy, it is to be expected that their use will expand and the number of exposures will increase in spite of the usual precautions taken in handling toxic substances.

Pharmacological and toxicological properties of decaboranes have been described by Tamas and Smith (ref. 14). The central nervous system is mainly responsible for clinical symptomatology, which is manifested by general depression, headache, tremors and seizures (ref. 1, 8-13). The cumulative effects of decaborane and a derivative identified as HEF-3 have been analyzed by Delgado and Back (ref. 4), and by Delgado, Back and Tamas (ref. 5). In these studies monkeys with electrodes permanently implanted in the brain were given 1 mg/kg decaborane or HEF-3 daily, resulting, after a few days, in the appearance of a typical pattern of electrical activity of the brain characterized by high frequency, high-voltage bursts, mainly localized in the hypothalamus, without spread to limbic structures or other cerebral areas. These electrical abnormalities coincided with depression, somnolence, generalized twitching and short motor seizures. The localized extension of the electroencephalographic abnormalities suggested a selective effect of decaborane on the hypothalamus or perhaps on motor structures located in its neighborhood, and this possibility has been investigated further in the present series of experiments.

METHODS AND MATERIALS

A total of 10 monkeys (*Macaca mulatta*) were used in our experiments. Under pentobarbital sodium anesthesia, and with aseptic precautions, assemblies of electrodes were permanently implanted in the brain of each animal with the aid of a stereotaxic instrument. Several pairs of electrodes were used in Monkeys Nos. 36, 37, 56, 96, and 98, and assemblies of multilead electrodes were used in Monkeys Nos. 30, 32, 33, and 34. Technical details of implantation may be found in previous publications (ref. 2, 3). One or two weeks after surgery each monkey was placed on a Brady chair, and recordings of electrical activity of the brain were taken with a Grass 8-channel electroencephalograph. Figure 1 shows the usual experimental situation.

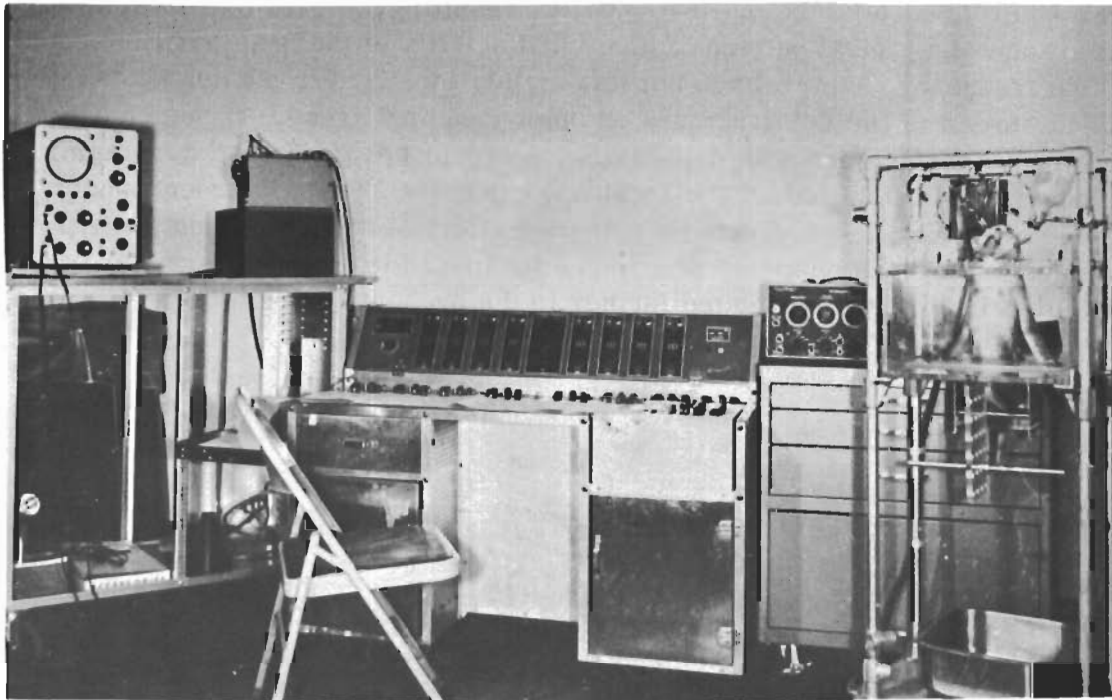


Figure 1 General setup for the Study. The Monkey Was Restrained in a Brady Chair. The Electrical Activity Was Monitored with an Oscilloscope and Recorded by an Electroencephalograph.

Contrails

In addition, the general behavior of the animal and its reactions towards offerings of food, and the gentle stroking with a glove were observed and noted. After the baseline of spontaneous electrical activity had been established for all intracerebral contacts, decaborane was given intraperitoneally once a day, dissolved in sterile olive oil in the amounts and according to the schedule shown in table I. The column under "total days" shows the total number of days through which the total amount of decaborane was given, taking into consideration the fact that no injections were made on Sundays. After the experiments were completed, the animals were sacrificed under anesthesia, perfused with 10 per cent formalin, and the brain was cut stereotaxically in blocks 10 mm wide. The location of the contacts was identified in frozen sections stained with thionine (figure 2), or in photographs prepared with fresh sections according to the method of Guzman et al (ref. 6).

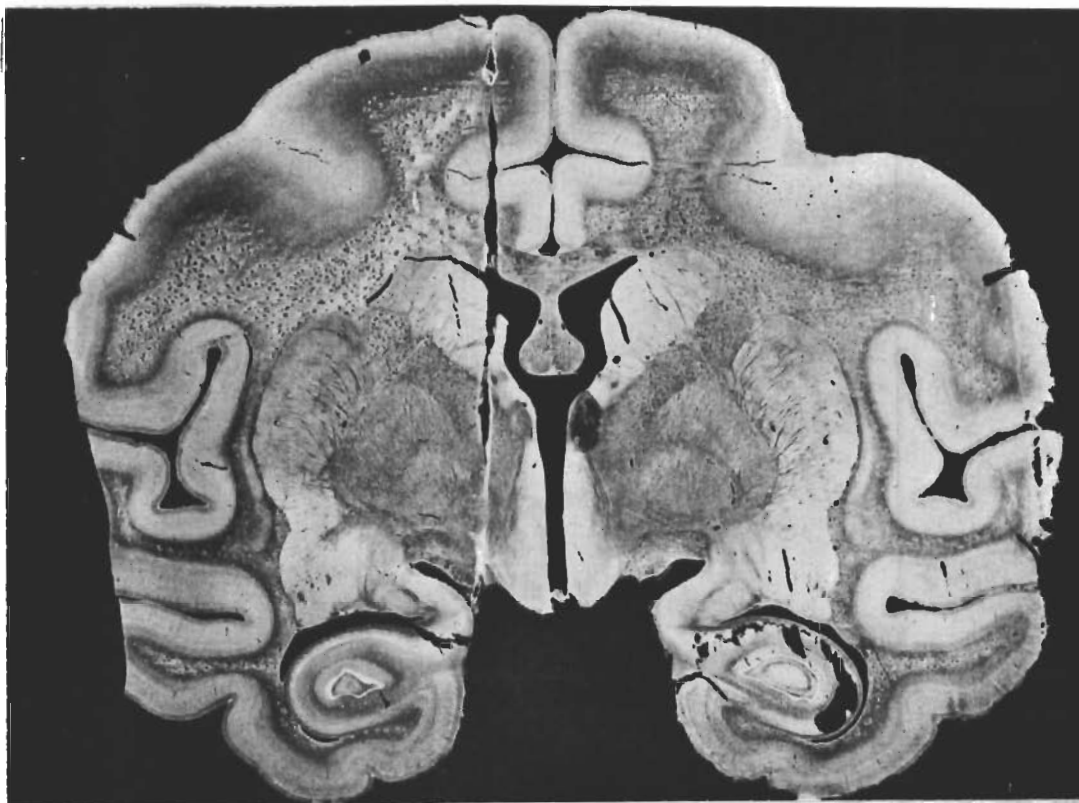

Figure 2 Histological Aspect of one Needle Tract after 2 months Implantation.

Contrails

Location of contacts:

Monkey #30, female, 4 kg

Electrode I

- #1 Lemniscus medialis
- #2 Nucleus reticularis mesencephali
- #3 Thalamus centre mediane
- #5 Thalamus, lateralis dorsalis
- #6 White substance lateral to cingulate gyrus
- #7 White substance below area 4

Electrode II

- #1 Reticular substance
- #2 Reticular substance
- #3 Inferior colliculus
- #5 Ventricle
- #6 White substance, lateral to cingulate gyrus
- #7 White substance below area 4

Monkey #32, female, 2.8 kg

Electrode I

- #1 Inferior part optic tract
- #2 Upper part optic tract
- #3 Internal capsule
- #5 Internal capsule
- #6 Caudate nucleus
- #7 Caudate nucleus

Monkey #33, female, 2.8 kg

Electrode I

- #1 Ventromedial hypothalamus
- #2 Dorsomedial hypothalamus
- #3 Internal capsule
- #5 Septum
- #6 Corpus callosum
- #7 Cingulate gyrus

Electrode II

- #1 Reticular substance
- #2 Ocular-motor nuclei
- #3 Central gray
- #5 Posterior commissure
- #6 Medialis dorsalis
- #7 Cortex

Monkey #34, male, 3 kg

Electrode I

- #1 Orbital cortex
- #2 White substance frontal lobes
- #3 White substance frontal lobes
- #5 White substance frontal lobes
- #6 Cingulate gyrus
- #7 Cingulate gyrus

Monkey #36, female, 2.9 kg

Electrode I

#1-2 Amygdala
#3-4 Hypothalamus
#5-6 Septum

Electrode II

#1-2 Cingulate
#3-4 Thalamus
#5-6 Caudate

Monkey #37, female, 3.5 kg

Electrode I

#1-2 Amygdala
#3-4 Hypothalamus
#5-6 Septum

Electrode II

#1-2 Cingulate
#3-4 Thalamus
#5-6 Caudate

Monkey #56, female, 3.5 kg

Electrode I

#1-2 Hypothalamus
#3-4 Thalamus
#5-6 Cingulate

Electrode II

#1-2 Substantia nigra
#3-4 Thalamus
#5-6 Corpus callosum,
cingulate

Monkey #78, male, 6.4 kg

Electrode I

#1 Internal capsule, Fr.7
#2 Pallidum
#3 Lateral cingulate
#4 Peduncle
#5 Gyrus hippocampi
#6 Pyriform cortex
#7 Pyriform cortex

Electrode II

#1 Internal capsule, Fr.6
#2 Internal capsule

Contrails

Monkey #96, female, 2.8 kg

Electrode I (left side)

#1-2 Cingulate gyrus (Fr. 24)
#3-4 Caudate (Fr. 16)
#5-6 Internal capsule (Fr. 20)
#7 Corpus callosum (Fr. 20)

Electrode III (right side)

#1-2 Cingulate gyrus (Fr. 23)
#3-4 Caudate (Fr. 15)
#5-6 Caudate (Fr. 19)

Electrode II (left side)

#1-2 White substance (Fr. 14)
#3-4 Thalamus (Fr. 11)
#5-6 Internal capsule (Fr. 22)
#7 Cingulate (Fr. 22)

Electrode IV (right side)

#1-2 White substance (Fr. 10)
#3-4 Thalamus (Fr. 11)
#5-6 Callosum (Fr. 22)

Monkey #98, male, 3.6 kg

Electrode I

#1-2 Uncus
#3-4 Amygdala
#5-6 Pallidum

(The notation Fr. followed by a number represents the stereotaxic coronal plane where the contacts were located. For example, Fr. 24 = coronal plane 24 mm frontal to interaural line.)

RESULTS

The amounts of decaborane given to each monkey are shown in table I, which indicates that 1 mg/kg in the present experimental series did not produce lethal effect in any case, even if total amounts as large as 14 mg/kg were given over a period of 17 days.

Daily doses from 2-5 mg/kg produced death in the 3 monkeys tested.

TABLE I

Administration of decaborane

Monkey #	Daily dose	# of doses	Total days	Total decaborane	Observation
30	1 mg	14	17	14 mg	depressed, shivers complete recovery
33	3 mg	4	4	12 mg	depressed, shivers death 3 days later
32	1 mg	6	6	6 mg	sleepy, shivers complete recovery
34	2 mg	3	3	6 mg	death one day later
36	1 mg	5	6	5 mg	sleepy, tremors complete recovery
37	1 mg	7	9	7 mg	depressed, tremors complete recovery
56	1 mg	5	6	5 mg	sleepy, tremors complete recovery
78	5 mg	1	1	5 mg	death in 18 hours
96	1 mg	12	14	12 mg	depressed, tremors complete recovery
98	1 mg	8	9	8 mg	depressed, tremors complete recovery

Contrails

Effect of 5 mg/kg A single injection of 5 mg/kg was tested in Monkey #78. One hour after the injection, sporadic twitches appeared in the left leg, which in some cases lasted several seconds. A few minutes later, tremors in the left arm and the left leg were observed, and were often recorded in the EKG leads, as shown in figure 3B. Three hours after decaborane administration, the monkey was depressed; the reactions to sensory stimulation were diminished; the tendinous reflexes were sluggish; the musculature was hypotonic; tremors and twitches in the extremities were observed from time to time, and the animal's eyes usually remained closed. However, it could easily be aroused, accepting and eating fruits which were offered. The tremors and twitches persisted at about the same intensity, but depression increased in the following hours, and the animal died 18 hours after the decaborane injection.

Electrical activity recorded from the internal capsule, pyriform cortex, hippocampus, peduncle, lateral geniculate and pallidum showed moderate modifications. There was some increase in fast activity one hour after the injection of the drug (compare figure 3A with 3B), which was more pronounced 6 hours later, and was more prominent in the internal capsule and peduncle than in other areas. However, the typical pattern of decaborane bursts found in chronic intoxication was not present in this case. Fast activity alternated with periods of slow waves, as shown in figures 3 C and D. Seven hours after decaborane administration, the increased depression of the animal coincided with increased high-voltage activity as shown in figure 3F. This activity, however, was related mainly to the fact that the eyes of the monkey were closed, and diminished when the eyes were opened.

Effect of 3 mg/kg The effects of repeated daily injections of 3 mg/kg of decaborane were investigated in Monkey #33. The first dose was asymptomatic. A few hours after the second injection, tremors appeared in different parts of the body, more noticeably in the extremities. The animal showed less general reactivity to sensory stimulation. Appetite was intact, and aggressiveness against the investigators remained normal. After the third dose, the monkey was noticeably depressed, somnolent, with tremors and twitches from time to time. The general depression increased after the fourth day of injection, when shivers were observed now and then coincident with bursts of fast electrical activity in the electroencephalogram. The animal was hypotonic and hyporeactive, but the aggressiveness against the investigators was still in evidence. After a total of 12 mg/kg had been injected in 4 days, the drug was discontinued. The monkey, however, did not recover, remained greatly depressed, with eyes closed without eating or drinking, resisted forced feeding, and died 3 days after the final dose of decaborane. The electrical activity, as shown in figure 4, changed considerably after the second injection of the drug. Typical high-voltage, high-frequency bursts were recorded from the leads located in the internal capsule (compare figures 4 A and 4B), and after the fourth dose of decaborane, this activity was present for periods of several

Contrails

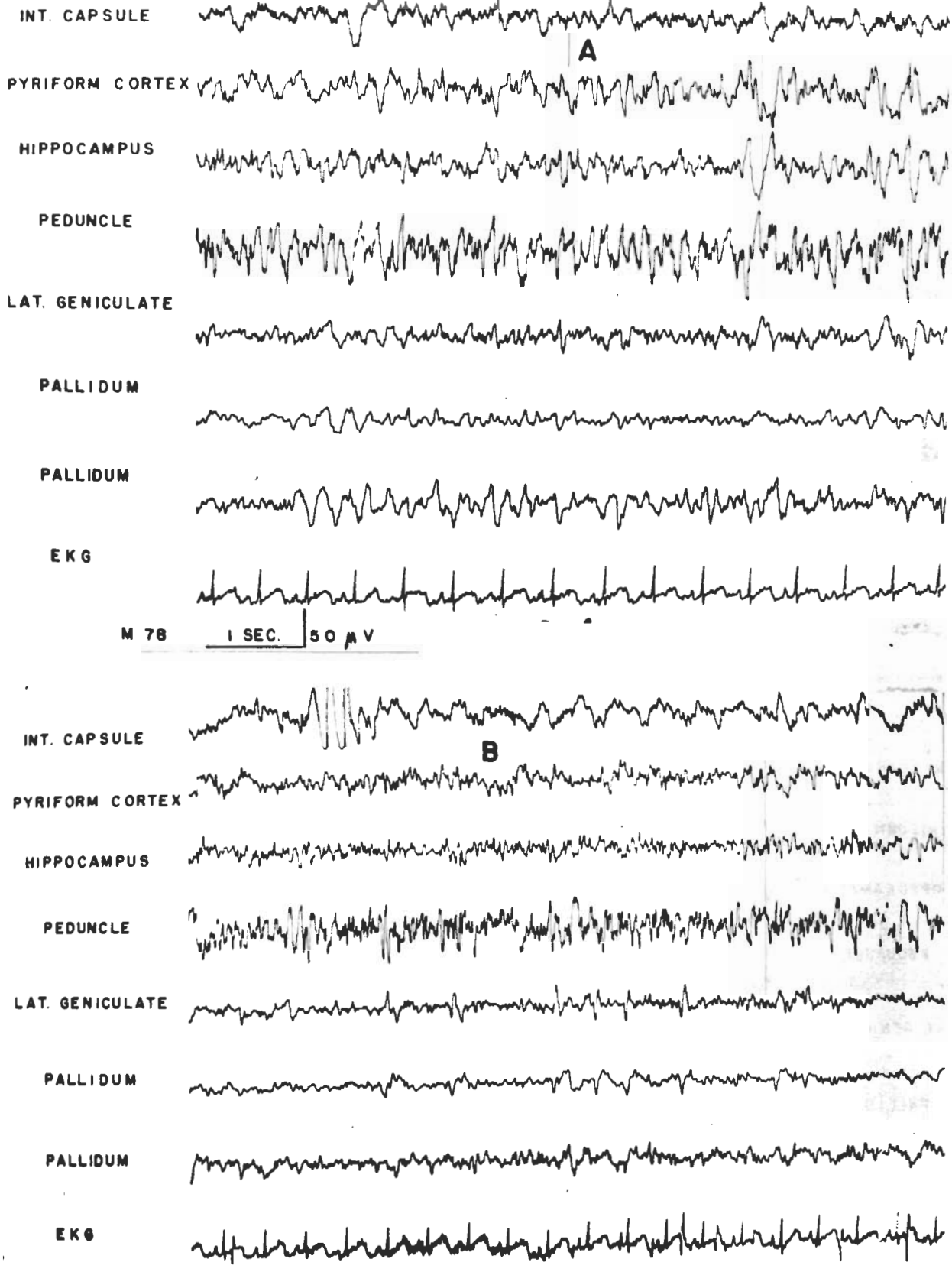


Figure 3 Monkey #78 Control is shown in A. B = Activity 1 Hour after Administration of 5 mg/kg of Decaborane

Contrails

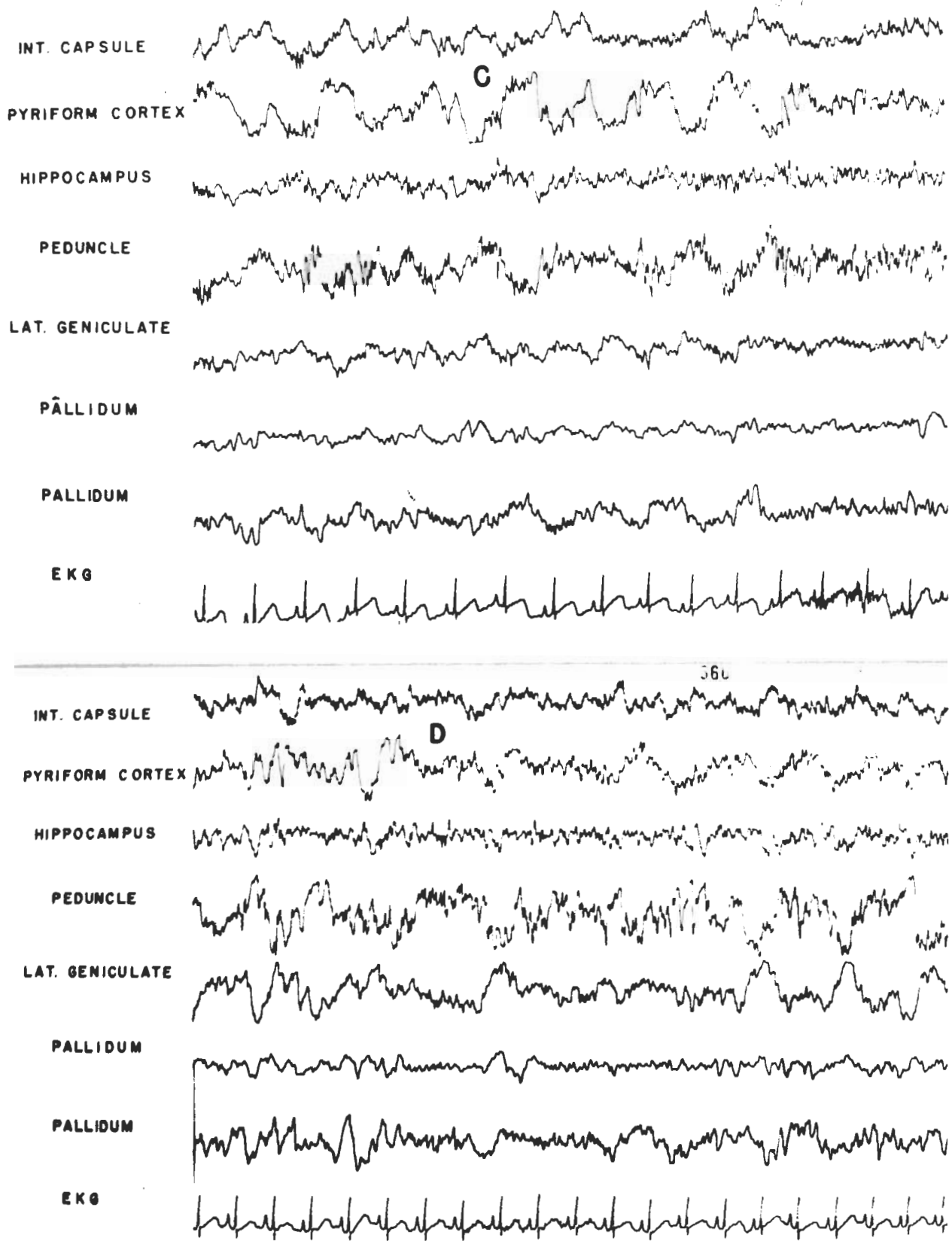


Figure 3 Monkey #78 C = Activity 2 Hours after Decaborane Administration
D = Activity 3 Hours after Decaborane

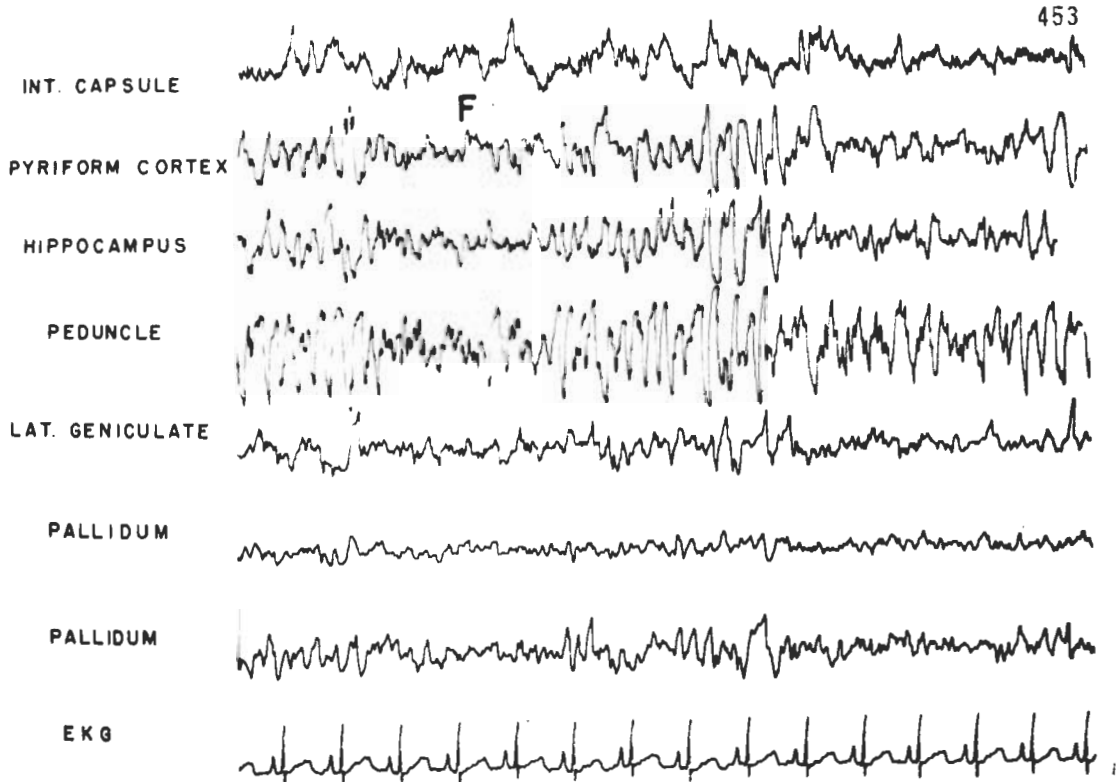
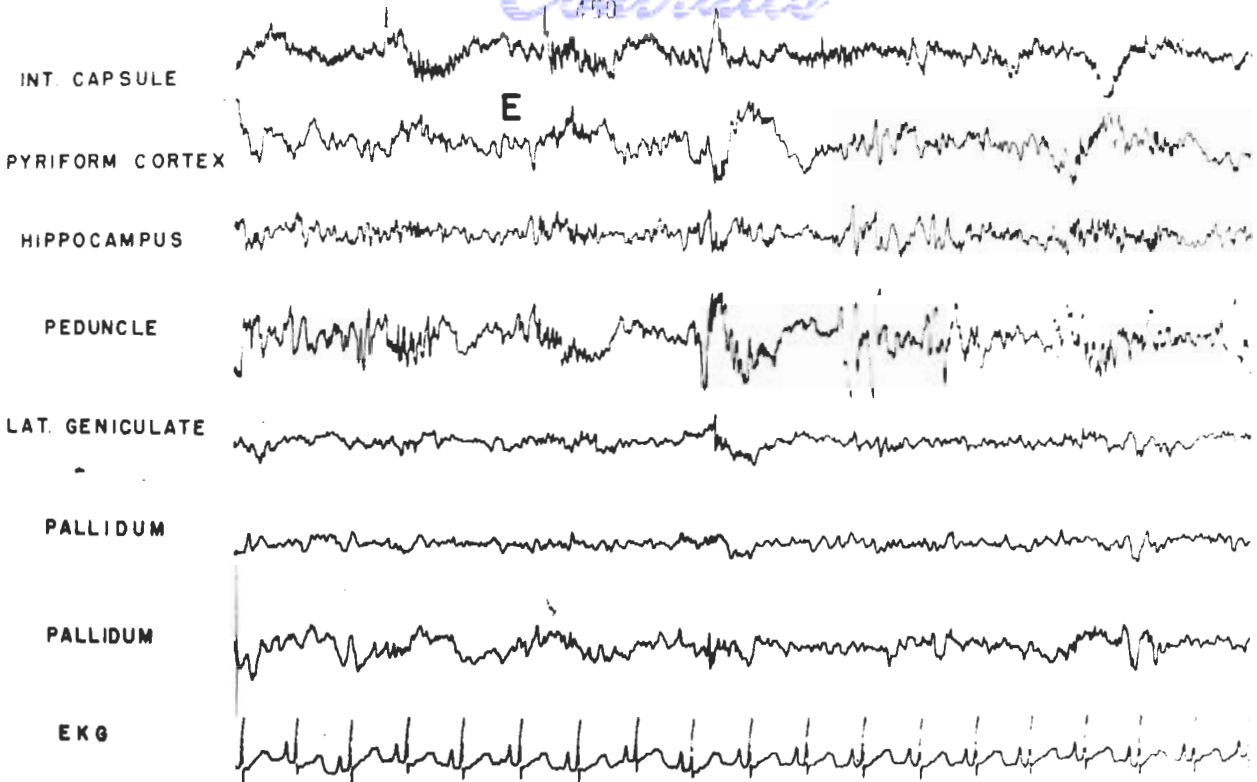
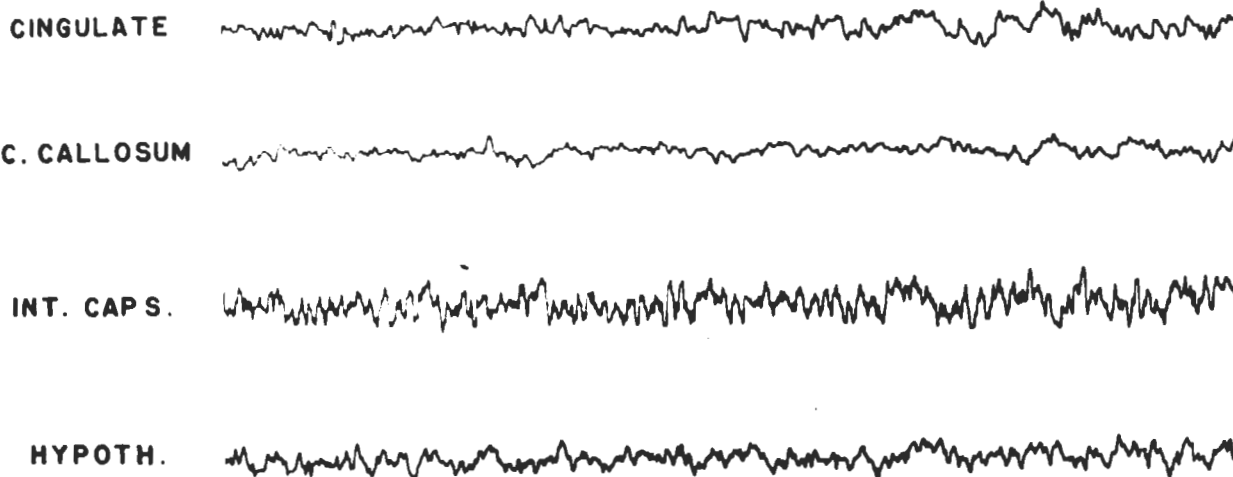


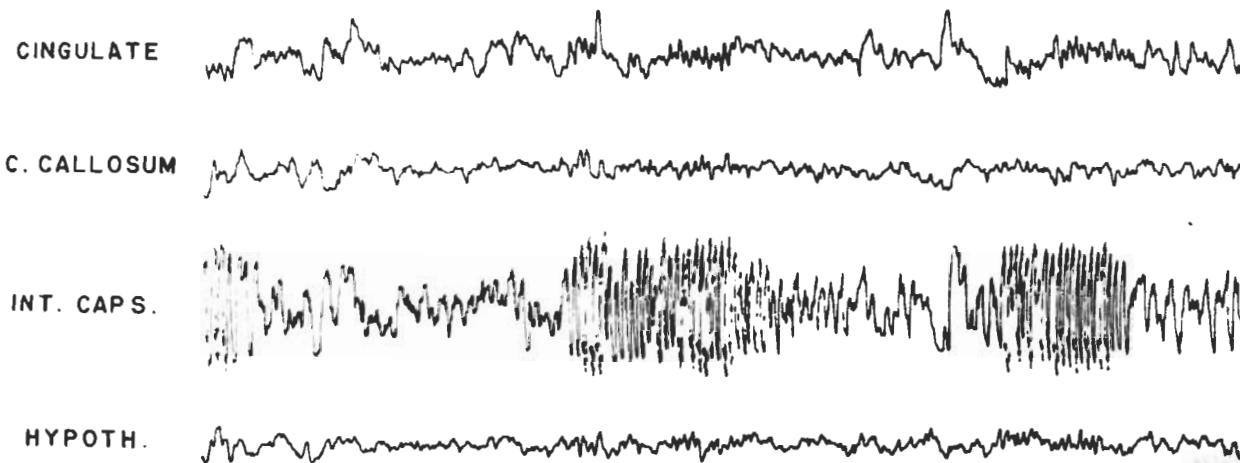
Figure 3 Monkey #78 E = 6 Hours after Decaborane F = 7 Hours after Decaborane

Contrails

A



B



C

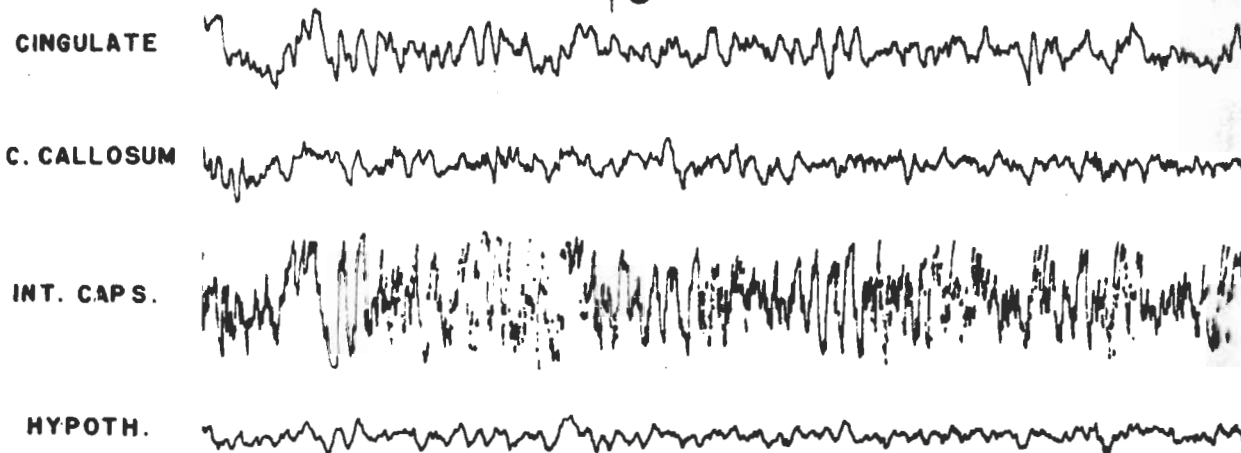


Figure 4 Monkey #33 A = Control B = Electrical Activity after Administration of the Second Dose of 3 mg/kg of Decaborane. Observe the Typical Bursts of High-voltage, Fast Activity in B, and the Long Run of High-voltage, Fast Activity in C, which Was Coincident with Tremors in the Animal. Note that the Abnormal Activity Is Localized to only Internal Capsule Contacts.

Contrails

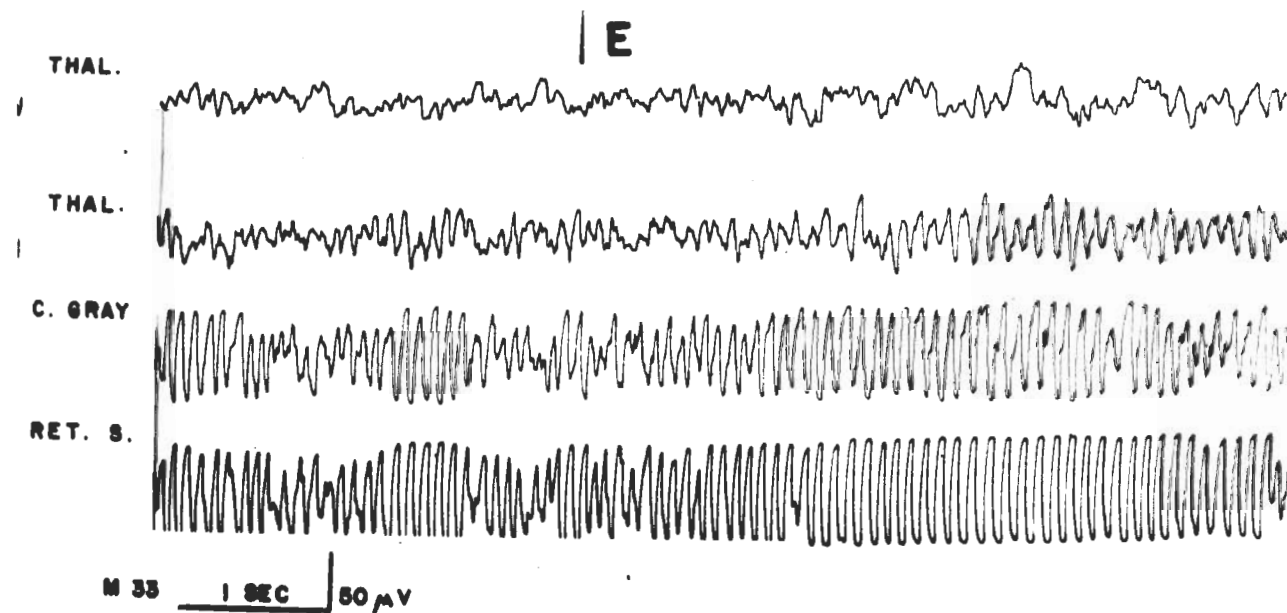
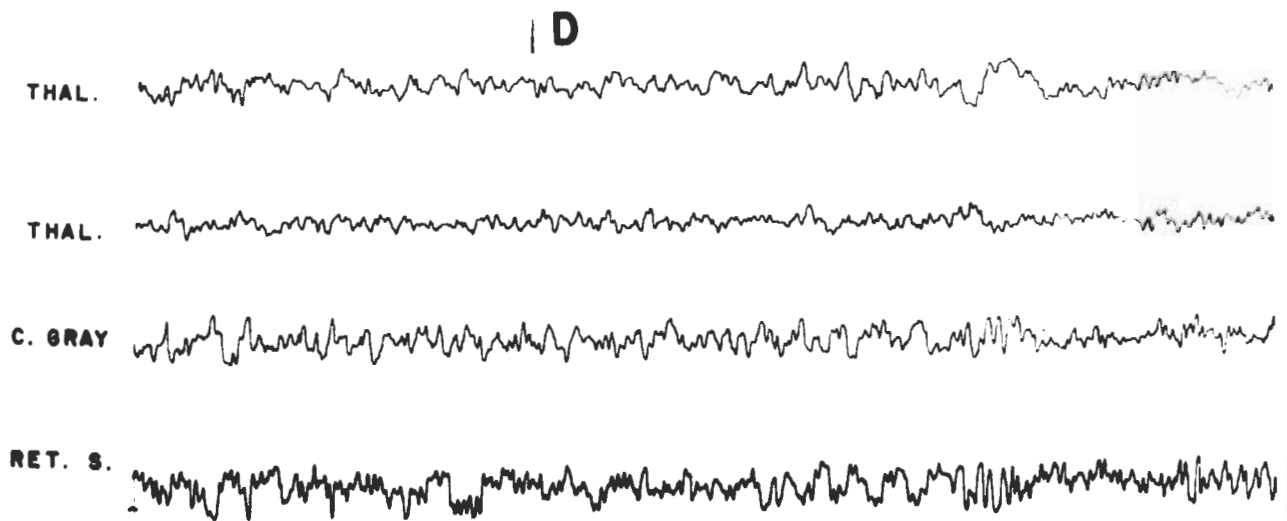


Figure 4 Monkey #33 D = Control E = After the 4th Dose of Decaborane.
Seizure-like Activity Was Recorded from the Central Gray and Reticular
Substance.

Contrails

minutes, and it was so fast that it could not be well recorded by the ink-writing pens (figure 4C). This fast activity was synchronous with tremors observed in the animal, and it should be emphasized that this impressive change in the electrical activity was recorded only from the contacts located in the internal capsule and the electrical disturbance was very moderate in the cingulate gyrus, corpus callosum and hypothalamus. As shown in figure 4E, considerable changes in electrical activity were also observed in the reticular substance as rhythmic regular high voltage, 10 cycles per second, which continued for periods of a few seconds up to one minute, alternating with periods of activity similar to those of the control records. No clear correlation between this electrical disturbance and clinical symptomatology could be found.

Effect of 2 mg/kg The effect of repeated daily injections of 2 mg/kg of decaborane was studied in Monkey #34. This animal was rather apathetic before the start of the experiment, and became somnolent after the second injection of decaborane. The third dose increased the depression, and the animal died the following day. In the autopsy the existence of a subcutaneous infection was confirmed, which could have contributed to the low resistance of the animal to the toxicity of decaborane. For this reason, results of this particular experiment were accepted with reservations.

Effect of 1 mg/kg The effect of daily injections of 1 mg/kg of decaborane was investigated in seven monkeys, as shown in table I. The first 2 injections were, in general, asymptomatic. After the second injection in 4 of the monkeys, and after the third injection in the other 3 animals, some somnolence was noted (figures 5 and 6). The animals were spontaneously less active when alone in their living quarters; when caught, they were less aggressive than during the control period, and jerks and tremors lasting a few seconds were observed, mostly in the extremities. The depression of the animals increased after the fifth or sixth dose, and appetite diminished in some animals.

The electroencephalographic activity presented typical changes with bursts of rapid activity coincident usually with tremors of the extremities. Voluntary activity often increased the tremor and the number of bursts. In the attempt to localize the origin of this fast activity, two areas emerged as most probable: the internal capsule at different levels, and the reticular formation at the mesencephalic level. As shown in figure 7, simultaneous electrical recordings from many structures demonstrated that the fast activity was absent from the caudate nucleus, cingulate gyrus, thalamus, and was recorded through contacts located at the internal capsule and in the white substance underneath cortical area 6.

Seizure-like activity appeared in 5 animals after the seventh or eighth dose of decaborane. As shown in figure 8 (Monkey #30), bursts of high-voltage 10 cycles per-second activity were recorded mainly from the reticular formation at the medullary level, and were more obvious in monopolar than in bipolar

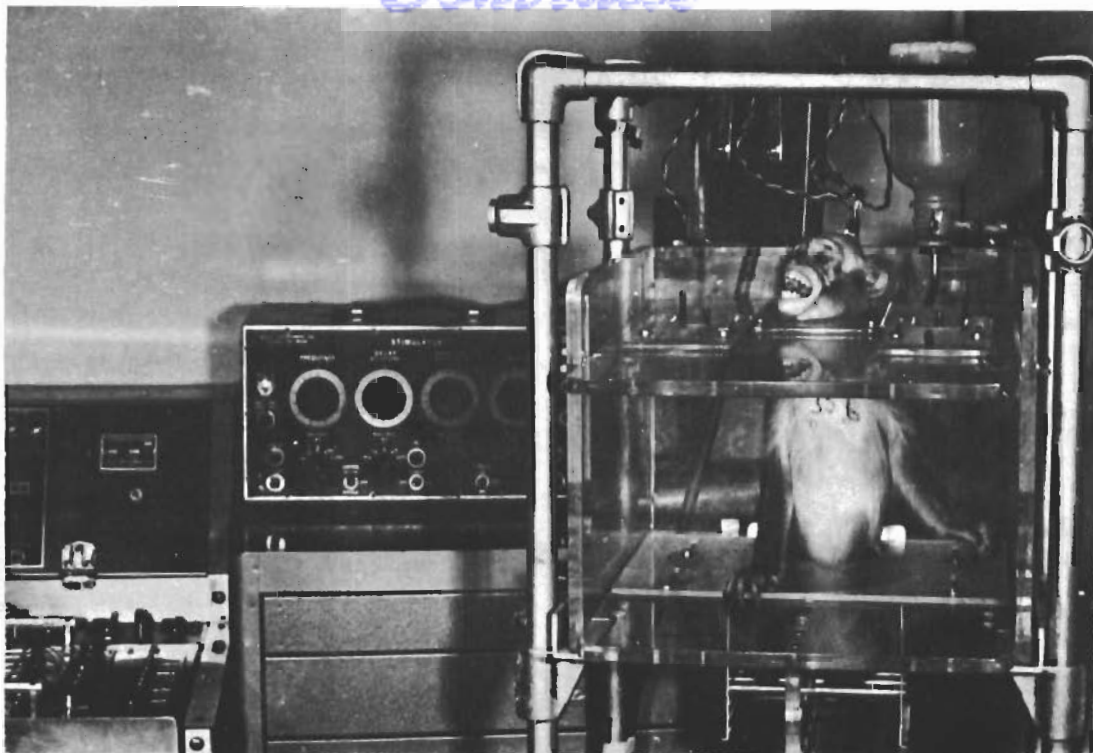


Figure 5 Normal Monkey is Attentive and Reactive to External Sensory Stimulation.

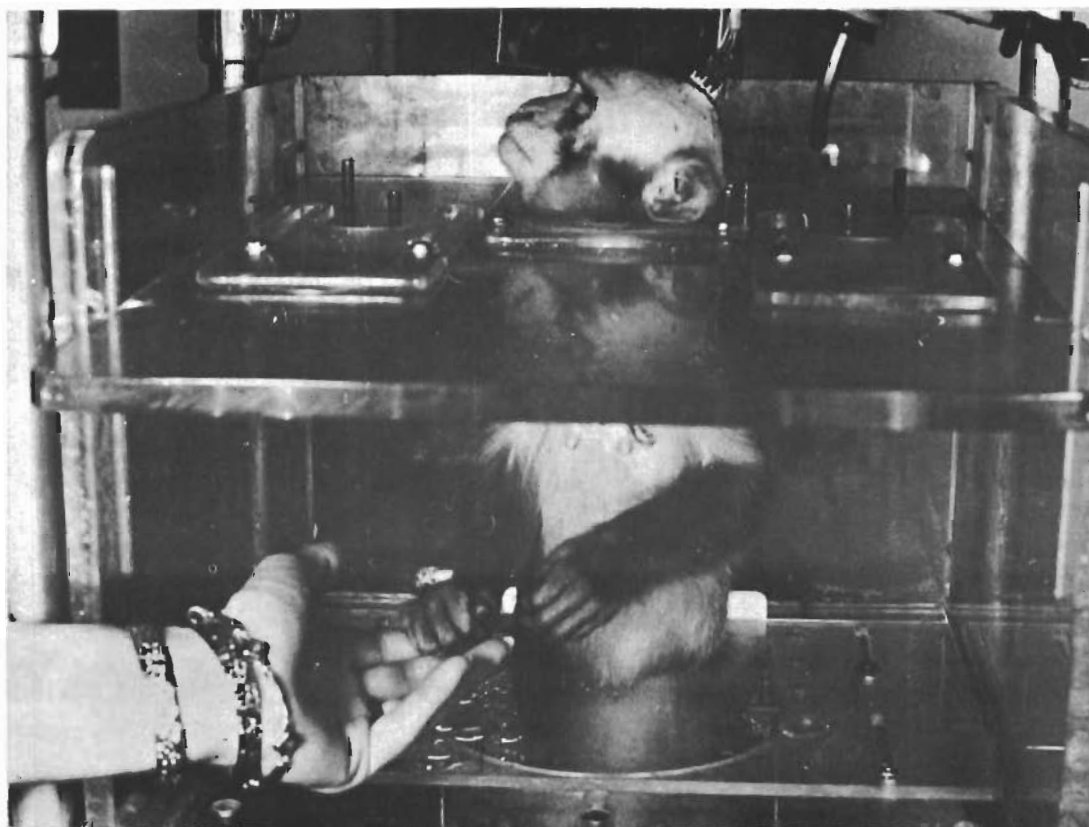


Figure 6 After 3 Daily Injections of 1 mg/kg of Decaborane, the Monkey Was Sleepy and Hyporeactive.

Contrails

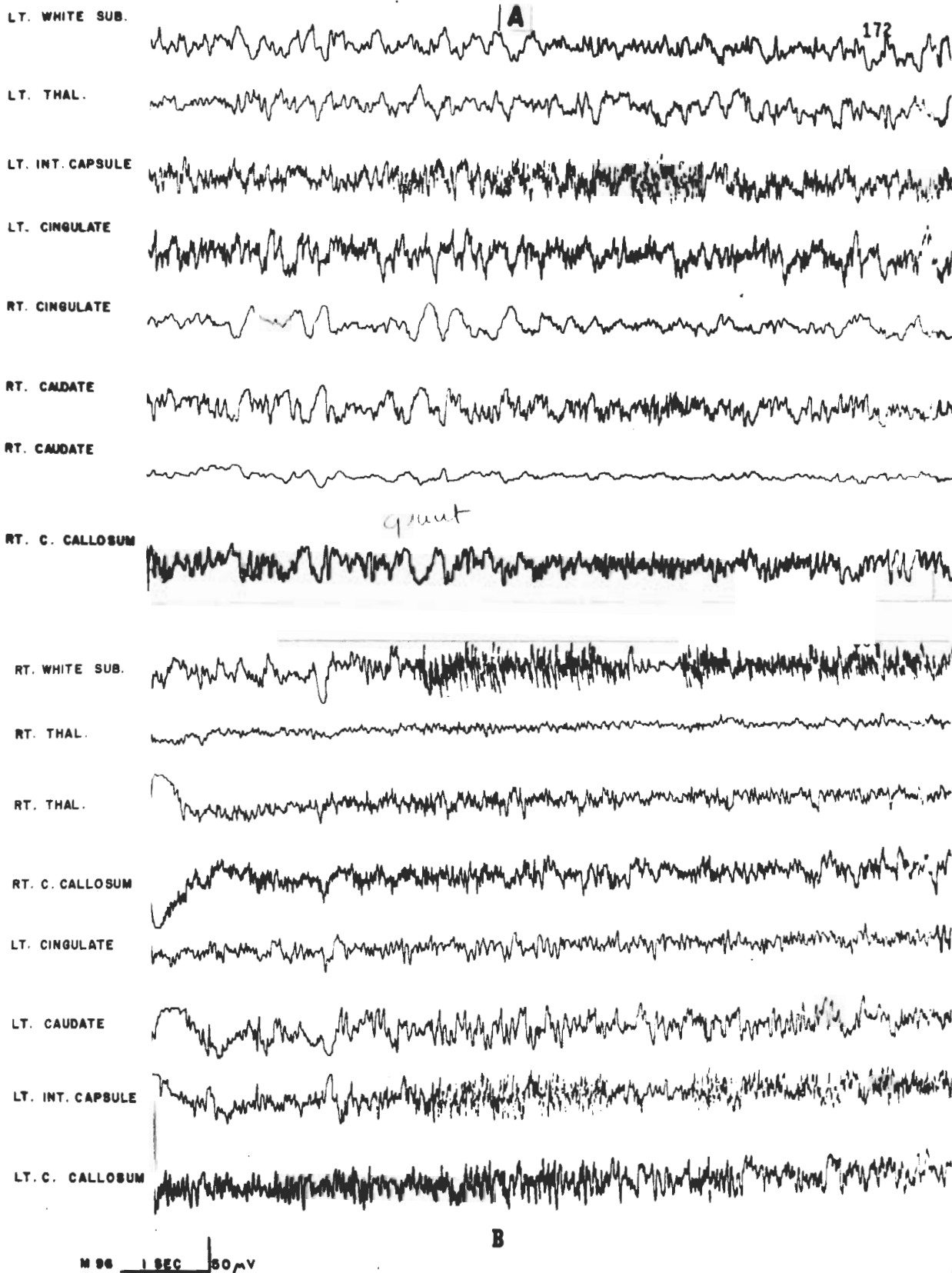


Figure 7 Monkey #96 After 5 Daily Injections of 1 mg/kg of Decaborane. Recordings from many Cerebral Structures Demonstrate that Typical Bursts of Fast Activity Were Localized in Motor Pathways and Absent in the Rest of the Explored Areas.

Contrails

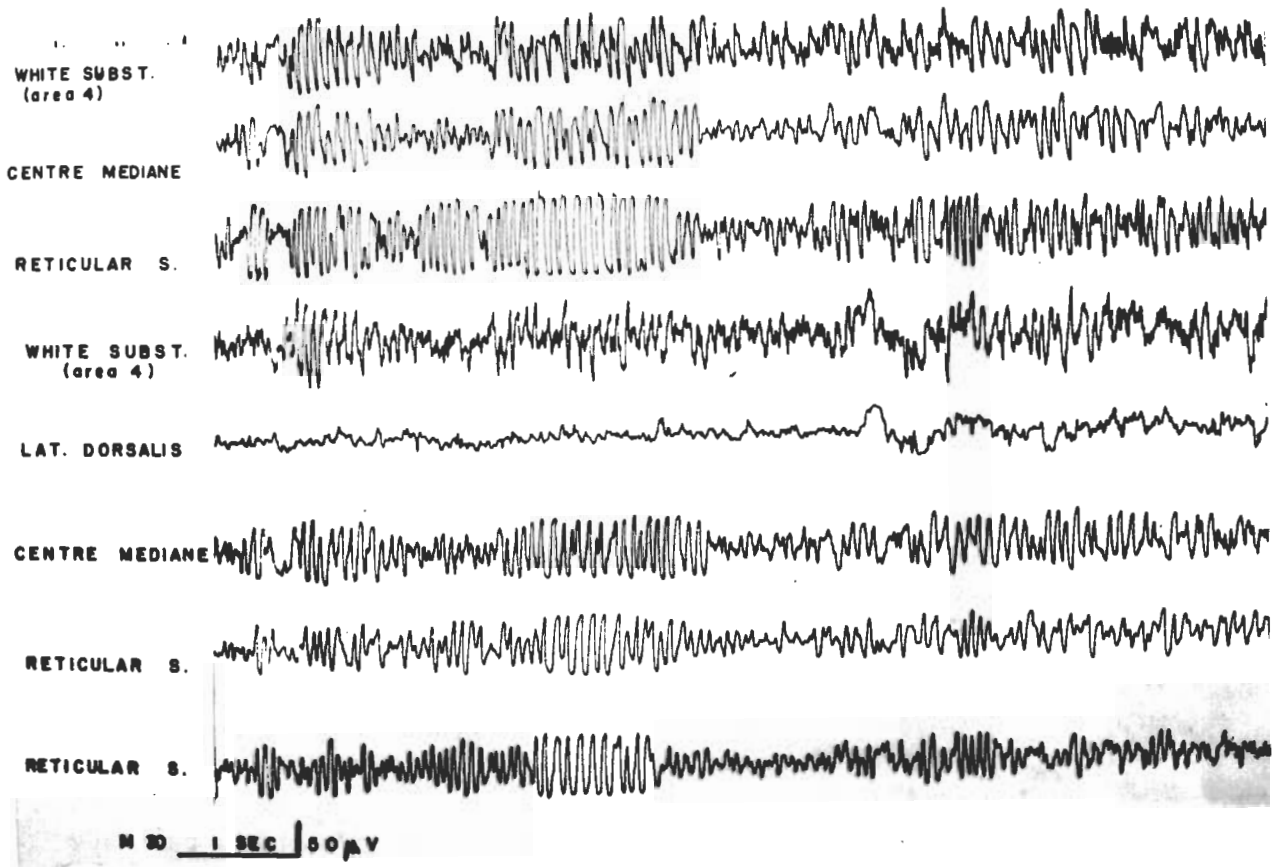


Figure 8 Monkey #30 After 8 Daily Injections of 1 mg/kg of Decaborane. Bursts of High-voltage Activity Were more Prominent in the Reticular Formation, but also Spread to other Structures. The First 3 Channels Are Monopolar Recordings. The Last 5 Channels Are Bipolar Recordings.

recordings. This activity, however, spread to several cerebral structures, and was also recorded from the thalamus, the white substance, and from other structures.

In spite of the considerable amount of decaborane which was given to several animals (see table I), in one case as high as 14 mg/kg over a period of 17 days, no lethal effect was recorded in any case, and the monkeys, upon withdrawal of the drug, continued anorexic with shivers and depression for 5 to 6 days, and eventually all of them recovered, with mobility, normal behavioral reactions, and spontaneous electrical activity indistinguishable from that of the control period.

DISCUSSION

In the intoxication produced by decaborane, two groups of CNS symptoms should be considered: 1) Diminished sensory reactions, somnolence, hypotonicity, hyporeflexia and general depression of behavior. 2) Increased motor responsiveness manifested by jerks, twitching, tremors, and in some cases, localized motor seizures.

The increased slow-wave activity, which was recorded in several monkeys, should not, in our opinion, be interpreted as a direct effect of decaborane intoxication, but rather as a secondary manifestation of animals with eyes closed, somnolent and depressed. A possible clue for this general depression might be the seizure-like activity recorded from the contacts located in the reticular formation. It is conceivable that hypersynchrony in this area may block the usual activating effect of the reticular formation on sensory input. This possibility could be proved or disproved by further studies, which would analyze the cortical modifications of evoked sensory responses (i.e., by sciatic stimulation), during electrical disturbance of the reticular formation induced by decaborane.

Our studies showed that decaborane intoxication disturbs motor pathways preferentially to the rest of the brain. Typical bursts of high-voltage activity, coincident with muscular tremors, were recorded from different points of the efferent motor path, and were absent in the frontal lobes, thalamus, hippocampus, caudate nucleus and other cerebral structures. Typical bursts of activity appeared in animals with contacts located in both internal capsule and lateral hypothalamus, but the voltage was higher in the former than in the latter, suggesting that neighboring hypothalamic areas (i.e. internal capsule), were responsible for the high-voltage hypothalamic activity (ref. 5). When the electrodes were located in the medial part of the hypothalamus, and therefore at a greater distance from the motor pathways, there was only a faint repercussion of the typical borane activity present in the other cerebral regions, as shown in figure 4B. The significance of the bursts of fast activity is not clear. They could represent a true disturbance of motor conduction, or could be just the electrical manifestation of circulating motor orders which are responsible for the clinical symptoms without giving indications of their true origin. We should emphasize that decaboranes are insoluble in water, but are liposoluble. It is therefore possible that highly myelinated structures, such as the motor axons, would be more susceptible to the effect of decaborane than other neural formations, poorer in myelin. It was interesting to note that the thalamus did not seem to be involved in decaborane intoxication, and this could explain the fact that localized convulsive phenomena remained limited to a small group of muscles, and did not become generalized in spite of its persistence through several days.

REFERENCES

1. Cole, V. V., D. L. Hill, and A.H. Oikemus, "Problems in the Study of Decaborane and Possible Therapy of Its Poisoning," A.M.A. Arch. Ind. Hyg. and Occupational Med., Vol 10, p 158, 1954.
2. Delgado, J.M.R. "Evaluation of Permanent Implantation of Electrodes within the Brain," EEG clin. Neurophysiol., 7, 637-644, 1955.
3. Delgado, J.M.R., "Chronic Implantation of Intracerebral Electrodes in Animals," Pp 25-36 in "Electrical Stimulation of the Brain," D.E. Sheer (Editor), Austin, Univ. Texas Press, 641 pp, 1961.
4. Delgado, J.M.R. and K.C. Back. Implantation and Use of Brain Electrodes for Toxicological Application. Wright Air Development Division Technical Report 61-609, Wright Air Development Division, Wright-Patterson Air Force Base, Ohio, August, 1960.
5. Delgado, J.M.R., K.C. Back, and A. A. Tamas, "Effect of Boranes on the Monkey Brain." Arch. int. pharmacodyn., Vol 141, p 262, 1963.
6. Guzmán, C., M. Alcaraz and A. Fernández, "Rapid Procedure to Localize Electrodes in Experimental Neurophysiology," Bol. Lab. Estud. méd. biol. (Mex.), 16, 29-31, 1958.
7. Lowe, H.J., and G. Freeman, "Boron Hydride (Borane) Intoxication in Man," A.M.A. Arch. Ind. Health, Vol 16, p 523, 1957.
8. Miller, D.F., A.A. Tamas, L. Robinson, and E. Merriweather, Cumulative Effects of Borane Toxicity as Revealed by a Clinical Test, Wright Air Development Division Technical Report 60-604, Wright-Patterson Air Force Base, Ohio, August, 1960.
9. Rozendaal, H.M., "Clinical Observations on the Toxicology of Boron Hydrides," A.M.A. Arch. Ind. Hyg. and Occupational Med., Vol 4, p, 257, 1951.
10. Svirbely, J.L., "Acute Toxicity Studies of Decaborane and Pentaborane by Inhalation," A.M.A. Arch. Ind. Hyg., Vol 10, p 298, 1954a.
11. Svirbely, J.L., "Subacute Toxicity of Decaborane and Pentaborane Vapors," A.M.A. Arch. Ind. Hyg., Vol 10, p 305, 1954b.
12. Svirbely, J.L., "Toxicity Tests of Decaborane for Laboratory Animals. I. Acute Toxicity Studies," A.M.A. Arch. Ind. Health, Vol 11, p 132, 1955a.
13. Svirbely, J. L., Toxicity Test of Decaborane for Laboratory Animals. II. Effect of Repeated Doses.: A.M.A. Arch. Ind. Health Vol 11, p 138, 1955b.
14. Tamas, A.A., and D. L. Smith, Health Hazards of Borane Fuels and Their Control, State-of-the-Art Report, Wright-Patterson Air Force Base, Ohio, October, 1958.