

**FOREWORD**

This work was performed in support of Project 6302, "Toxic Hazards of Propellants and Materials," Task 630201, "Toxicology," and Task 630206, "Toxicology Support." The work was performed from March 1962 to December 1963 in the Toxic Hazards Branch, Physiology Division, Biomedical Laboratory. Valuable assistance rendered by Captain Donald S. Gisler and Mr. Crate Spradlin of the Veterinary Medical Branch, and by Dr. Anthony A. Thomas, Mrs. Mildred K. Pinkerton, Miss Barbara Reynolds, Major James Prine, TSgt Gregory W. Craig, and A2C Charles E. Witchett, of the Toxic Hazards Branch, is gratefully acknowledged.

Experiments reported herein were conducted according to the "Principles of Laboratory Animal Care," established by the National Society for Medical Research.

# *Contrails*

**ABSTRACT**

Twelve rhesus monkeys received daily doses of hydrazine ranging from 5 to 20 mg/kg and totaling from 4 to 20 injections. Seven monkeys received 20 injections of 1,1-dimethylhydrazine at 10 mg/kg. All animals lost weight during the experiment.

In the hydrazine-treated group of monkeys, serum glutamic oxaloacetic transaminase and bilirubin rose with doses of 20 mg/kg, with more than a twentyfold increase of SGOT in two animals. Most of those receiving 20 mg/kg exhibited loss of appetite, vomiting, lethargy, and severe weakness. Microscopic examination revealed lipid accumulation in the liver, myocardium, kidney, and skeletal muscle. Massive liver necrosis was observed in one animal. In those monkeys receiving UDMH, blood glucose rose significantly toward the end of the experiment. Some lipid was deposited in the heart, liver, and kidney, but to a much lesser degree than was observed with hydrazine, and it could only be demonstrated with special fat stain.

Rats given from 3 to 23 doses of 10 or 20 mg/kg/day hydrazine did not show marked fatty changes as observed in the monkeys.

**PUBLICATION REVIEW**

This technical documentary report is approved.

*Wayne H. McCandless*  
WAYNE H. McCANDLESS  
Technical Director  
Biomedical Laboratory

# *Contrails*

# **PATHOLOGY AND TOXICOLOGY OF REPEATED DOSES OF HYDRAZINE AND 1,1-DIMETHYLHYDRAZINE IN MONKEYS AND RATS**

**Roman L. Patrick, Captain, USAF, MC**

**Kenneth C. Back, Ph.D.**

## **INTRODUCTION**

Hydrazine ( $N_2 H_4$ ) has been reported to cause accumulation of lipid in the liver (refs 1-5) and kidney (ref 6) after both single and multiple doses. Our past experience with 1,1-dimethylhydrazine [ $(CH_3)_2 N_2 H_2$ ], a methylated hydrazine derivative, has not shown this compound to cause deposition of lipid in the kidney and liver of rats, monkeys, and dogs with single doses up to 100 mg/kg. However, we had not determined the effects of multiple doses of UDMH in any animal other than the rat (ref 7). The work in rats indicated that there was no liver or kidney lesion with daily doses of 10 mg/kg/day for 20 days. To our knowledge comparable multiple dose experiments with either compound have not been done using primates. Preliminary studies indicated a striking species difference in the degree of pathologic alterations between rats and monkeys that received hydrazine. This report concerns the comparative pathology and toxicology of repeated doses of hydrazine in rats and monkeys and of UDMH in monkeys.

## **MATERIALS AND METHODS**

All experiments were performed using Practical Grade 1,1-Dimethylhydrazine (UDMH) and Hydrazine obtained from Eastman Organic Chemicals, Rochester, New York.

Male rats of the Sprague-Dawley strain weighing from 308 to 386 gm were employed. One group of 25 rats received 10 mg/kg hydrazine by the intraperitoneal (ip) route, daily, 5 days a week for 5 weeks. Simultaneously, another group of 25 rats received 20 mg/kg/day for the same period of time. The hydrazine solutions were prepared fresh daily by dilution with distilled water. Body weights were recorded twice each week. One group of five control rats received no injections and was

otherwise handled in the same manner as the hydrazine-treated animals. Another group of 10 control rats received 0.25 ml distilled water ip throughout the course of the experiment. As many as five animals from each dose regimen (either 10 or 20 mg/kg) were sacrificed each week to study any progressive development of pathologic alterations. The rats were anesthetized with ether, and blood was obtained from the femoral vessels for differential white cell count, hematocrit, and serum glutamic oxaloacetic transaminase (SGOT) (ref 8). All organs were fixed in buffered formalin. Fats were stained with oil-red-O. All tissues were stained with hematoxylin and eosin (H&E).

The effects of both hydrazine and UDMH were studied utilizing monkeys. Prior to the administration of compounds, the following blood baseline studies were performed on each monkey four times during a 9-day period: white cell and differential counts, hemoglobin, hematocrit, SGOT, and plasma "true" glucose. Blood analyses were repeated twice weekly during the course of the exposure regimens.

Seven rhesus monkeys, both males and females, weighing from 3.2 to 3.5 kg received 20 doses of UDMH at a level of 10 mg/kg ip. Simultaneously, six monkeys weighing 2.7-3.6 kg received hydrazine at a dose level of 5 mg/kg/day, as indicated in groups A and B, table 1. Doses in all cases were administered daily except on weekends. In two animals (group B) the hydrazine dosage was progressively increased at the end of the 5 mg/kg/20-day dose regimen, since none of the monkeys showed marked clinical illness during the low dose schedule. Six additional monkeys weighing from 3.6 to 4.1 kg were given either four or five doses of 20 mg/kg/day (group C) to compare them with monkeys that had previously received multiple lower doses before receiving the 20 mg/kg dose. In all animals, weights were recorded weekly. The animals were killed under pentobarbital sodium anesthesia, and complete necropsies were performed. Tissues from 10 monkeys that had not received hydrazine or UDMH were processed along with those from the treated monkeys in the manner previously described for rats.

## **RESULTS**

### **Hydrazine-Treated Rats**

#### **Clinical Behavior**

All control rats and those that received 10 mg/kg hydrazine survived the experiment. There appeared to be a diminished food intake during the first week. The maximum weight loss occurred during the first 10 days of the experiment (figure 1). Subsequently, the treated rats gained weight but did not reach control values.

In the group receiving 20 mg/kg hydrazine, 10 of 25 rats died during the experiment between the 8th and 21st doses. Weakness, lethargy, and a diminished food intake were noted. Partial epilation occurred, particularly about the abdomen and groin. Convulsions were observed in two animals, in one after 10 and in the other after 17 doses. Red frothy fluid was present about the mouth and nose of two others,

TABLE 1

HYDRAZINE DOSE IN MONKEYS

Group	No. of Animals	Dose mg/kg	No. of Doses	Total Dose mg/kg
A	4	5	20	100
B	2	5	20	
		10	8	
		20	4-5	260-280
C	6	20	4-5	80-100

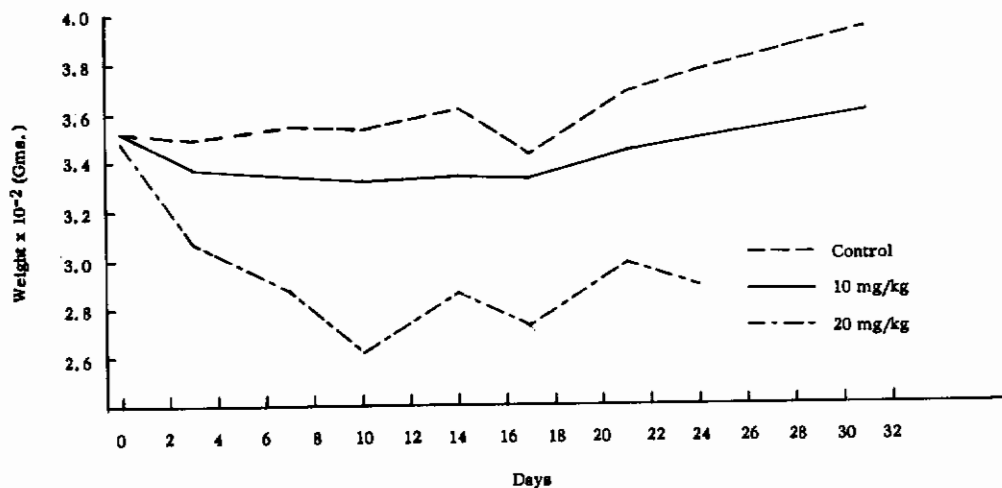


Figure 1. WEIGHT CHANGE IN RATS RECEIVING HYDRAZINE, BASED ON THE AVERAGE WEIGHT OF SURVIVING ANIMALS

Dosage was begun after the initial weighing.

possibly resulting from convulsions. The maximum weight loss occurred during the first 10 days of the experiment and was more pronounced than in those receiving 10 mg/kg (figure 1).

**Laboratory Determinations**

In the 10 mg/kg group, hematocrit values were lowest in those rats killed after 13 doses (table 2). No significant difference could be detected in the differential white cell counts between control and treated rats. SGOT values tended to be higher in the rats that received three doses than at any other dose schedule (table 3).

In the 20 mg/kg group, hematocrit (table 2) and SGOT (table 3) showed trends similar to those described with the 10 mg/kg dose.

TABLE 2

HEMATOCRIT IN RATS TREATED WITH HYDRAZINE

No. of Animals	Hydrazine Dose	No. of Doses	Mean Value Vol %	Range Vol %
15	Control	--	49	47-53
5	10 mg/kg	3	47	44-50
5	10 mg/kg	8	47	45-49
5	10 mg/kg	13	38	32-42
5	10 mg/kg	18	42	40-44
4	10 mg/kg	23	45	44-47
5	20 mg/kg	3	48	43-51
5	20 mg/kg	8	48	43-56
2	20 mg/kg	13	30	23-36
2	20 mg/kg	18	36	34-38
1	20 mg/kg	23	39	---

TABLE 3

SGOT IN RATS TREATED WITH HYDRAZINE

No. of Animals	Hydrazine Dose	No. of Doses	Mean Value (Units)	Range (Units)
15	Control	--	65	34-100
5	10 mg/kg	3	106	76-136
5	10 mg/kg	8	41	34-47
5	10 mg/kg	13	55	34-74
5	10 mg/kg	18	61	36-74
5	10 mg/kg	23	61	42-68
5	20 mg/kg	3	109	82-136
5	20 mg/kg	8	67	34-148
2	20 mg/kg	13	58	49-66
2	20 mg/kg	18	37	26-48
1	20 mg/kg	23	48	---



**Pathologic Alterations**

There was no pathologic alteration in the 10 mg/kg group that could be attributed to hydrazine. In the 20 mg/kg group, gross observation revealed severe pulmonary congestion and edema in four rats that received 18 or more doses. Two animals in which such changes were noted were among the 10 that died.

Microscopic examination of H&E stained tissue sections revealed changes consistent with a diagnosis of chronic murine pneumonia in the majority of animals. Such changes were also present in the control group. There was slight vacuolization of hepatic cells in seven animals (figure 2), five of which received three doses and two of which received eight doses of 20 mg/kg. Oil-red-O stains confirmed that such vacuoles represented the accumulation of fat within cells. This alteration was more prominent in portal and midzonal areas. Oil-red-O stains of heart and kidney failed to demonstrate fat.

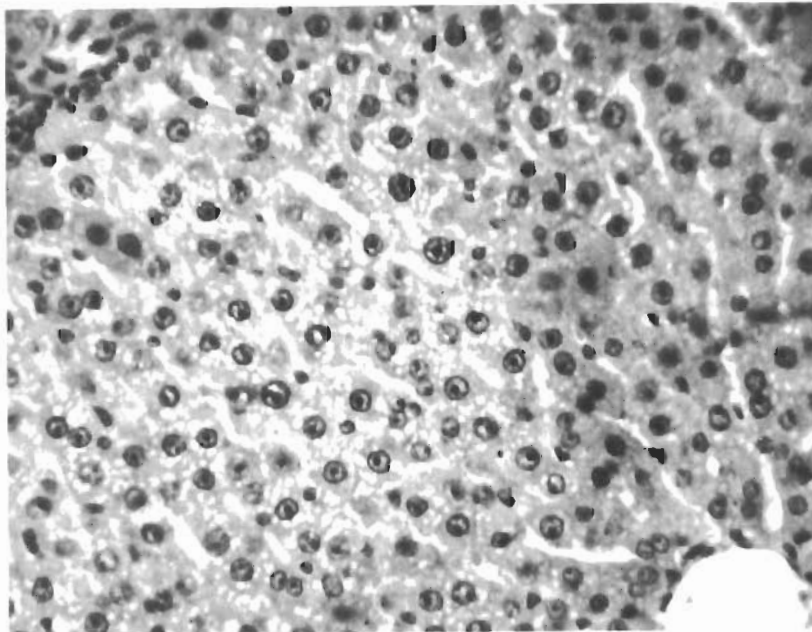


Figure 2. LIVER OF RAT RECEIVING HYDRAZINE,  
20 mg/kg/day

Note the small cytoplasmic vacuoles mostly  
in the midzonal region. H&E stain; x320

**Hydrazine-Treated Monkeys**

**Clinical Behavior**

There was no obvious sign of clinical illness in the four monkeys that received doses of 5 mg/kg/day or in the two that received additional doses of 10 mg/kg/day. All monkeys that received 5 mg/kg/day lost weight, ranging from 0.4 to 0.9 kg. The two monkeys that received additional larger doses exhibited no further loss. During the experiment, none of the monkeys regained its initial weight.

Seven of the eight monkeys in groups B and C vomited, exhibited lethargy and weakness; and one had tremors. Clinical signs developed at 20 mg/kg regardless of whether the animals had received previous doses.

**Laboratory Determinations**

At the repeated dose level of 5 mg/kg hydrazine, both hemoglobin and hematocrit mean values dropped slightly during the experiment (figures 3,4). No significant changes were noted in the white cell or differential counts.

The results of glucose determinations are summarized in table 4. There was a slight increase in mean blood glucose values after a dose of 20 mg/kg/day; however, the change does not constitute a significant difference.

SGOT baseline determinations yielded a mean value of  $28 \pm 15$  (SD) Sigma Frankel units. Terminal levels were not significantly altered in those monkeys receiving 5 mg/kg daily. In those receiving a dose of 20 mg/kg, however, there was a marked terminal elevation ranging from 78 to 5920 units.

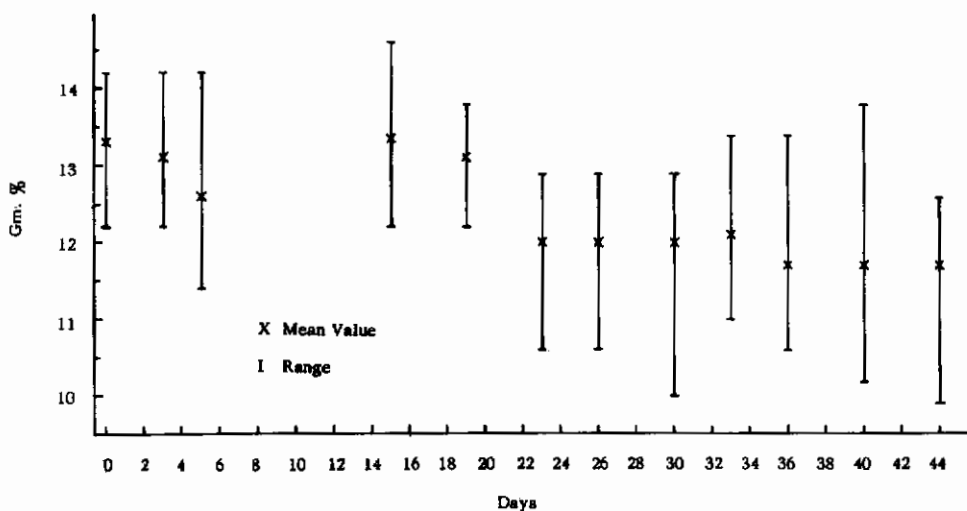


Figure 3. HEMOGLOBIN IN MONKEYS RECEIVING HYDRAZINE, 5 mg/kg/day

Dosage was begun on the 15th day.

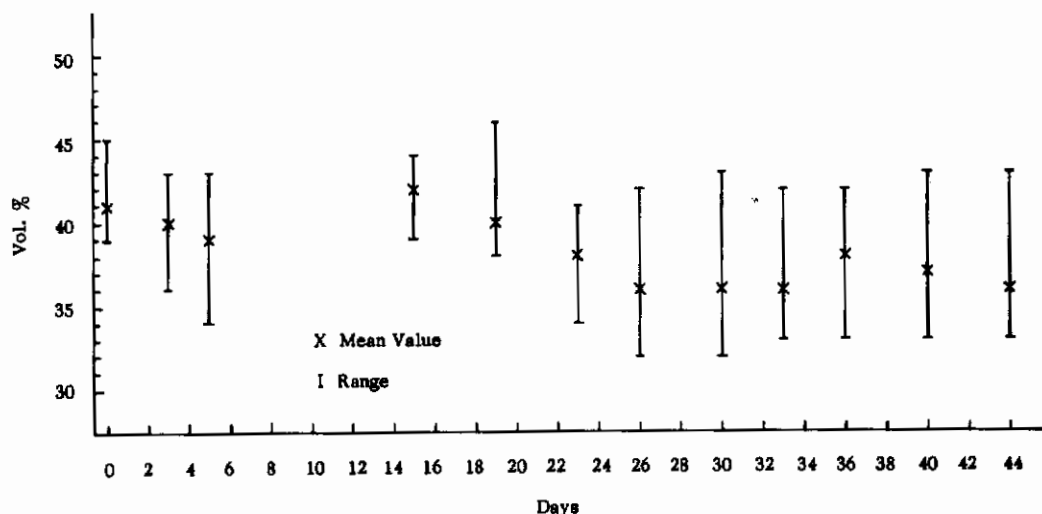


Figure 4. HEMATOCRIT IN MONKEYS RECEIVING HYDRAZINE,  
5 mg/kg/day

Dosage was begun on the 15th day.

TABLE 4

EFFECTS OF HYDRAZINE AND UDMH ON BLOOD GLUCOSE IN MONKEYS

Treatment	No. of Determinations	Mean Value mg%	SD
None	60	91	±18
Hydrazine			
5 mg/kg	6	110	±13
20 mg/kg	5	121	±48
UDMH			
10 mg/kg	7	173	±36

### Pathologic Alterations

Gross alterations of lungs were present in most monkeys in the form of a few scattered small gray-yellow nodules secondary to lung-mite (*Pneumonyssus semicola*) disease and not related to the experimental procedure. Acute ulceration of the duodenum was present in one animal that received five doses of 20 mg/kg (group C). The most significant gross alteration consisted of a uniformly pale, yellow-tan, slightly enlarged liver in all the animals receiving 20 mg/kg. In one animal receiving four doses of 20 mg/kg (group C), the liver was unusually friable with alternating yellow and well-demarcated dark red areas.

Histologic findings consisted of fatty changes in the liver, kidney, and heart. The most marked lipid accumulation was noted in monkeys dosed with 20 mg/kg/day for 4 or 5 days (group C). The liver was involved in all six animals; however, there was a considerable variation in the severity of the lesion, ranging from a moderate peri-portal and mid-zonal accumulation of lipid to markedly fatty livers with cellular distortion (figure 5). In one instance there was extensive peri-portal necrosis. With this dosage the kidney (figures 6,7,8) and heart (figure 9) also showed considerable fatty change. The fatty change in the kidneys was most conspicuous in proximal tubules. In some animals there were subnuclear deposits of lipid, and in others the entire cytoplasmic component contained lipid.

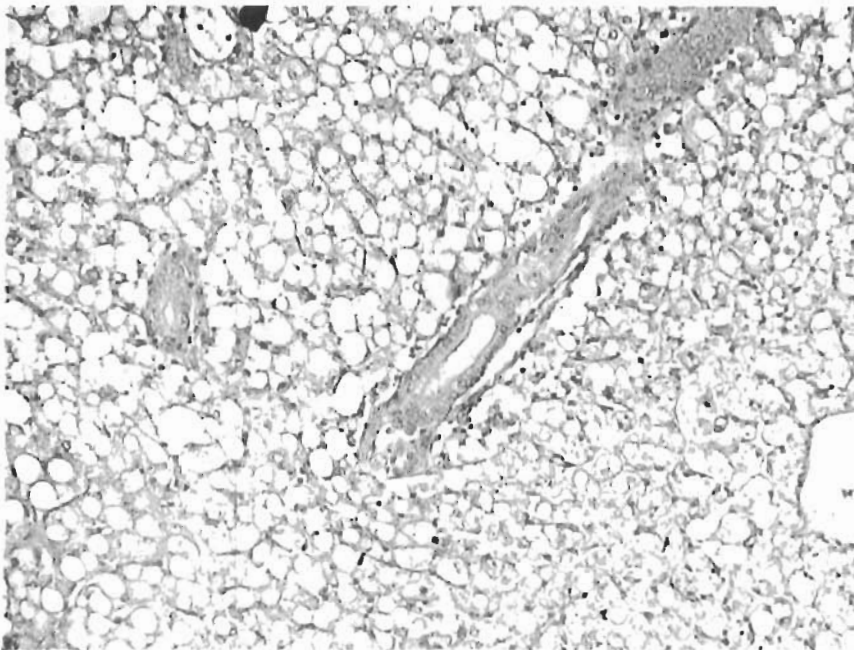


Figure 5. (left)

LIVER OF MONKEY  
RECEIVING HYDRAZINE,  
20 mg/kg/day

Note the large vacuoles  
distorting hepatic cells  
in all portions of the  
lobule. Compare with  
figure 2. H&E stain;  
x128

Figure 6. (right)

KIDNEY OF MONKEY  
RECEIVING HYDRAZINE,  
20 mg/kg/day

There are numerous small  
vacuoles adjacent to the  
basement membrane.  
H&E stain; x460

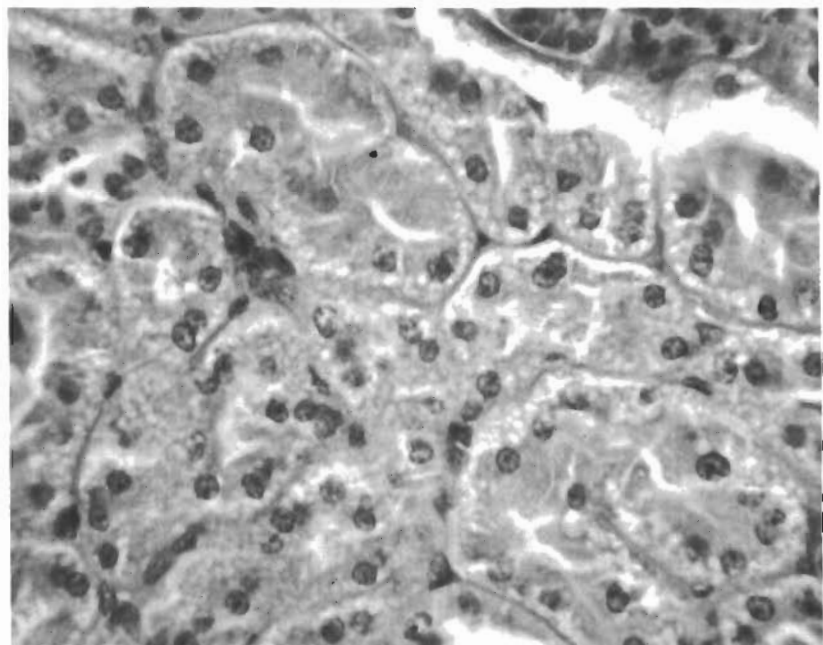


Figure 7. (right)

KIDNEY OF MONKEY  
RECEIVING HYDRAZINE,  
20 mg/kg/day

The dark areas in proximal tubules represent lipid. The distal tubules contain very little lipid. Oil-red-O stain; x128

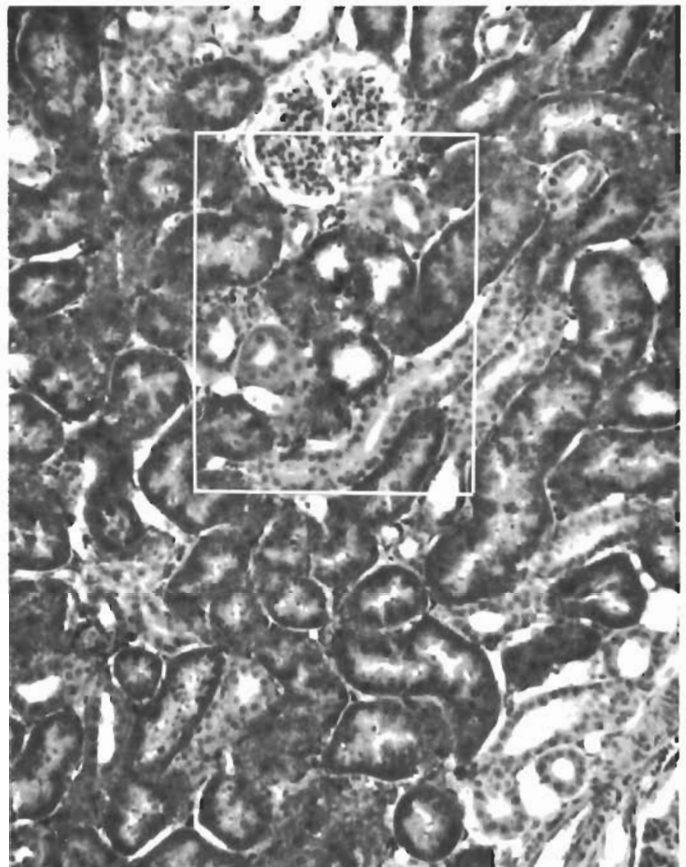
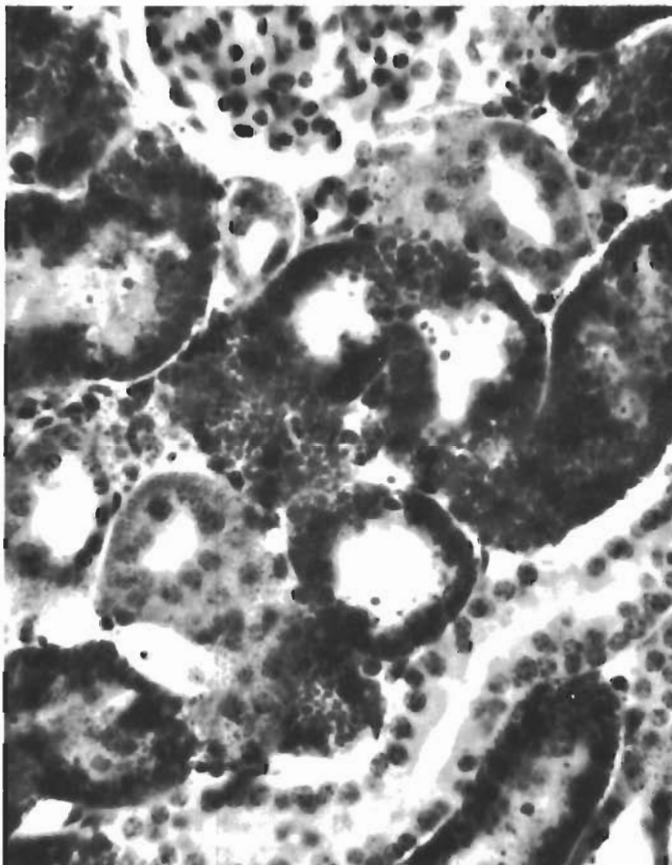


Figure 8. (left)

HIGHER MAGNIFICATION OF  
THE SAME SECTION SHOWN  
IN FIGURE 7

Oil-red-O stain;  
x440



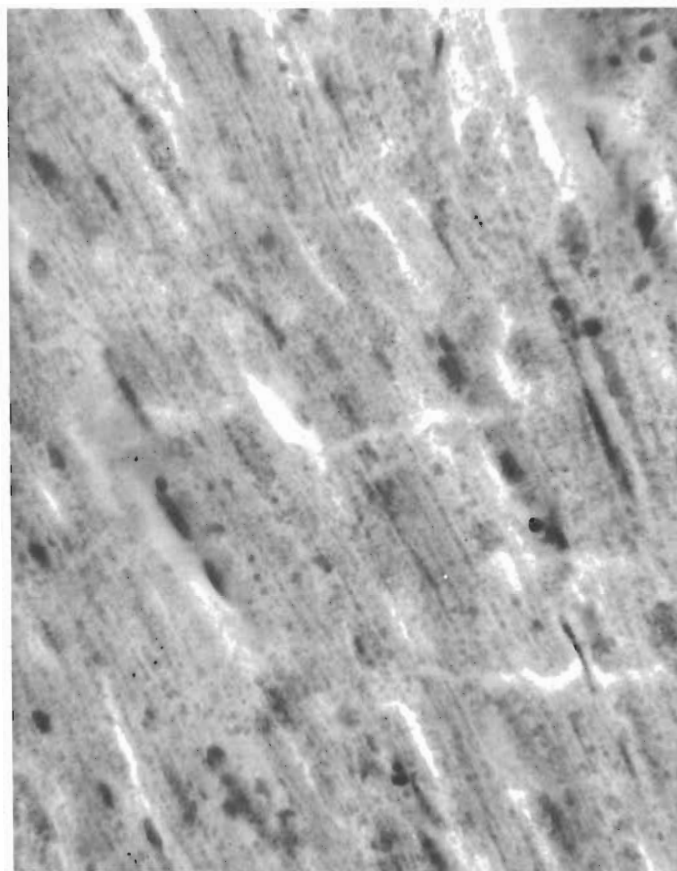


Figure 9. HEART OF MONKEY RECEIVING HYDRAZINE,  
20 mg/kg/day

Note the lipid. Oil-red-O stain; x440

In the myocardium, fat was present in the form of droplets, approximately 0.5 - 4 microns in diameter. In some animals this was a focal change; in others, the entire section was uniformly involved. This myocardial change was observed at all dosages of hydrazine but was not observed in the 10 untreated animals. The most severe fatty change was observed in monkeys of group C. Fat stains of skeletal muscle performed on three animals of group C revealed the same type of fatty alteration as observed in the myocardium.

In group A (20 doses of 5 mg/kg) there was a moderate amount of lipid in the liver and kidney of one of the four animals. Fat was demonstrated in the myocardium of three animals.

Those monkeys receiving the graded doses of hydrazine (group B) showed significantly less accumulation of lipid in the liver than was observed in animals of group C, receiving four or five doses of 20 mg/kg/day without previous smaller doses. Moreover, the heart and kidney were essentially normal. This occurred despite the fact that these monkeys received the largest total dose.

## UDMH Treated Monkeys

### Clinical Behavior

At the dose regimen used (10 mg/kg/day) all seven monkeys lost from 0.2 to 0.8 kg weight during the experiment. Like the hydrazine treated animals, the maximum weight loss occurred early in the experiment, but two of the seven animals had regained their initial weight by the fourth week. UDMH caused no other noticeable effects.

### Laboratory Determinations

Hematological studies, including hemoglobin, hematocrit, white blood cell counts, and differential counts, showed no significant alteration from baseline levels. Terminal SGOT determinations revealed no elevation over baseline values. Glucose determinations after 20 injections of UDMH, 10 mg/kg, showed a significant elevation (table 4).

### Pathologic Alterations

Gross examination revealed no change that could be attributed to the experimental procedure. Microscopic examination of H&E stained tissue sections revealed no lesions, but oil-red-O stains revealed a slight amount of lipid about the central vein in the liver of one animal. In another animal, there were small droplets of fat about the tubular membrane in the kidneys. Two monkeys had significant amounts of stainable lipid in the heart (figure 10); there were trace amounts in two others.

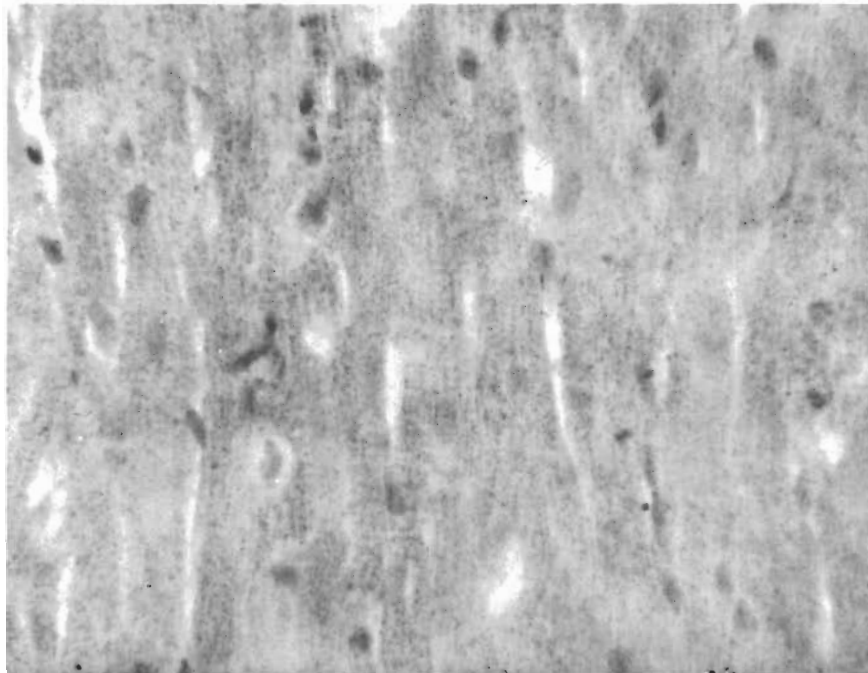


Figure 10. HEART OF MONKEY RECEIVING UDMH (10 mg/kg/day) WITH LIPID ACCUMULATION Oil-red-O stain; x440

**DISCUSSION**

When these experiments were initiated, the literature indicated that a single, large dose of hydrazine would readily produce accumulation of fat in the rat liver. For this reason, we started with a dose that was deemed high but nonlethal over a 20-day period. Consequently, a 10 mg/kg/day dose of hydrazine was used in the rat (approximately one-sixth of the acute  $LD_{50}$ ) and 5 mg/kg/day was used in the monkey. Contrary to our expectations, this dose did not produce fatty infiltration of the liver in the rat, and only one of the four monkeys showed significant fatty changes. Therefore, the dose in monkeys was increased first to 10 and then to 20 mg/kg/day, in order to provoke histological response.

Based upon our previous experience with UDMH in both rats and monkeys, we doubted that significant fatty changes could be produced at all. Monkeys that were protected with pyridoxine had received four to six lethal doses of 100 mg/kg within a period of 18 months and showed no demonstrable hepatic lesions with H&E preparations (ref 7). On the basis of this experience we thought that daily administration of 10 mg/kg UDMH (one-sixth of the  $LD_{50}$  for monkeys) for 20 days would be a sufficiently high dose to provoke liver lesions if, in fact, such changes occur. Indeed, in these monkeys receiving UDMH, some lipid was deposited in the heart, liver, and kidney, but to a much lesser degree than observed with hydrazine, and could be demonstrated only by special fat stains.

Another significant finding in this study is the marked difference in hydrazine-induced fatty alterations between rats and monkeys at a dosage of 20 mg/kg. The monkey is much more susceptible to the development of liver and kidney lesions from hydrazine than the rat. The marked difference in terminal SGOT values between the two species also reflects this feature. In addition, bilirubin levels were as high as 3.6 mg percent and we noted that the serum was icteric. Lipid accumulations in the kidney and heart were not observed in rats with 20 mg/kg/day for 20 doses, and were negligible in the liver when compared with the markedly fatty livers observed in monkeys receiving the same dose for only 4 days. In spite of the paucity of demonstrable anatomical injury in rats receiving such high doses, the toxic effects are nonetheless apparent in terms of clinical observations, weights, hematocrit, and the death of 10 of 25 animals. Convulsions probably contributed to death in several rats. It seems reasonable to postulate that there is a "threshold" effect with hydrazine in rats since Amenta et al (ref 5) have shown marked fatty reversible changes with a single dose of 56 mg/kg.

With special fat stain we were able to demonstrate lipid accumulation in the myocardium in monkeys receiving both hydrazine and UDMH. To our knowledge this lesion has not been described previously in relation to these compounds, although Forbus (ref 9) states that lipid accumulation in the heart and skeletal muscle is one of the most characteristic anatomic features of phosphorus poisoning. We have observed the same change in both monkeys and dogs in association with injury not related to hydrazine or UDMH. Pathogenesis of this lesion remains obscure; it has been observed by others (ref 10) in association with hemorrhagic shock in dogs. In the present study, there appeared to be no direct relationship between heart and



liver lesions. The myocardial alteration was present in treated animals in which there had been no clinical illness.

Dominguez et al (ref 6) reported that the reversible nature of kidney and liver lesions in rats was demonstrated within 72 hours after a single dose. In our study, only one monkey out of seven receiving hydrazine at 20 mg/kg/day exhibited hepatic necrosis, and there was a gradation of fatty change in the others. In some of the monkeys there were numerous small vacuoles with no appreciable distortion of cells, while in others hepatic cells were greatly distended by a single large vacuole with the nucleus in an eccentric position. In those animals with no cellular necrosis or severe cellular distortion, it seems that tissue damage would be reversible. Nonetheless, the severity of the general clinical illness was so great in some monkeys receiving 20 mg/kg that recovery would not have occurred even if tissue damage were reversible.

There is some indication, although not conclusive, that rats receiving hydrazine in this study became less susceptible to its effects after repeated daily doses. For example, SGOT values were slightly higher in those animals sacrificed after only three doses than in those receiving many more doses (see table 3). When fat was observed in the liver, it occurred in those animals receiving eight or less doses. Weights and hematocrits show similar trends, particularly in the group receiving 10 mg/kg/day.

One of the conspicuous findings in this study was the elevation of blood glucose following repeated doses of UDMH. The mechanism is presently being investigated.

**LIST OF REFERENCES**

1. Weatherby, J.H., and A.S. Yard, "Observations on the Subacute Toxicity of Hydrazine," A.M.A. Arch. of Industrial Health 11: 413, 1955.
2. Comstock, C.C., L. Lawson, H. E.A. Greene, and F.W. Oberst, "Inhalation Toxicity of Hydrazine Vapor," A.M.A. Arch. of Industrial Hygiene and Occupational Med. 10: 476, 1954.
3. Wells, H.G., "Pathological Anatomy of Hydrazine Poisoning," J. Exper. Med. 10: 457, 1908.
4. Beyer, K.H., "Protective Action of Vitamin C Against Experimental Hepatic Damage," A.M.A. Arch. Int. Med. 71: 315, 1943.
5. Amenta, J.S., and E.H. Johnston, "Hydrazine - Induced Alterations in Rat Liver," Lab. Invest. 11: 956, 1962.
6. Dominguez, A.M., J.S. Amenta, C.S. Hill, and T.J. Domanski, "Morphologic and Biochemical Alteration in the Kidney of the Hydrazine Treated Rat," Aerospace Med. 33: 1094, 1962.
7. Back, K.C., and A.A. Thomas, "Pharmacology and Toxicology of 1,1-Dimethylhydrazine (UDMH)," Amer. Industrial Hyg. Assoc. J. 24: 23, 1963.
8. SGOT, Colorimetric, Sigma Technical Bulletin 505, Sigma Chem. Co., 3500 Dekalb St., St. Louis 18, Mo., January 15, 1961.
9. Forbus, W.D., Reaction to Injury, Vol II, p 122, The Williams and Wilkins Co., Baltimore, Md., 1952.
10. Martin, A.A., and D.B. Hackel, "The Myocardium of the Dog in Hemorrhagic Shock," Lab. Invest. 12: 77, 1963.